

# Facial Skin Antiaging Using a Novel Radio Frequency Technology

N.Caballero, M.Herrero, M.A.Trelles

Instituto Médico Vilafortuny/FUNDACIÓN ANTONI GIMBERNAT  
E-43850 CAMBRILS/Tarragona, Spain (imv@laser-spain.com)

## Introduction

The treatment of the skin for skin rejuvenation, using radiofrequency (RF) devices, is common practice in aesthetic medicine (1). Treatments in skin aesthetics carried out with monopolar or bipolar RF (2,3), offer advantageous results, particularly for the formation of new collagen, as a consequence of the thermal effect that takes place inside the skin due to the absorption of electrical energy (4). The passage of the RF current in dermis produces irritation, followed by a tissue repair response leading to the development of new collagen. Although the effects produced by RF are not specific, they are of great interest when evaluating its efficiency because they are simple treatments to perform and are practically risk-free leading to few or no secondary reactions or complications.

We present a study of patients treated on the face and neck with new bipolar RF technology called AMFLI, with the aim of improving the skin condition, flaccidity and the appearance of wrinkles.

## Patients and method

20 females were recruited whose ages ranged from 40 to 60 years (average age 48), and whose phototypes corresponded to types II to V. The treatment areas were the neck, the chin area, the middle and lower third of the face and the periocular region (Table 1). Six sessions were performed at fortnightly intervals on all patients. Each patient was

informed as to the nature of the study and was given details of the treatment process. All accepted to take part in the treatment programme and signed a form of informed consent, also for their cases to be photographically documented. The study was approved by the Ethics Committee of the Antoni de Gimbernat Foundation

Prior to the start of the first session, face-on, profile and 45° photographs were taken of patients. Photographs were taken with a SONY Mavika DSC-H1 digital camera, with a macro lens, with light and background conditions kept uniform for all cases. Photographs were repeated under the same conditions one month after the last treatment (6<sup>th</sup> session).

## THE DEVICE

Treatment was performed using the *Thermalipo<sup>TM</sup> II* bipolar RF system (Thermamedic Ltd., Alicante, Spain), which incorporates novel Automatic Multifrequency and Low Impedance (AMFLI) technology. The system's microprocessor constantly monitors the return of the current from the handpiece, acting as an indicator of tissue impedance (resistance). There is a correlation between impedance and temperature and therefore the AMFLI system automatically monitors the temperature in the treated area and as a result it emphasises the appropriate frequency according to the changes of the tissue impedance (or temperature). Consequently, the frequencies generated and emphasized by the device, which are higher for more superficial work and lower for deeper action in tissue, vary the depth of penetration. As a result, skin is heated progressively, starting from deep in the dermis going upwards reaching the outer layers of the epidermis leading to highly homogenous and rapid volumetric heating of tissue. Thanks to this feedback system, RF frequency variation can be well and precisely controlled.

The handpiece, which is linked to the console by a cable that transmits the electrical energy, has a surface area of 3.3 cm<sup>2</sup>, where the electrodes are housed. The energy

generated between the electrodes (at the lowest frequency of 1 MHz) penetrates to approximately 5-10mm below the skin surface, corresponding to a maximum of half of the 2cm separation between the electrodes of the handpiece. For the treatment, a transmitter gel is used in order to achieve optimal coupling of the electrodes.

AMFLI technology is capable of rapidly depositing high amounts of RF electrical energy which, upon absorption turns into a thermal effect in tissue. The patient does not experience pain during treatment but as heat progressively accumulates in the dermis, the thermal effect propagates in all directions towards the epidermis as well, and is detected in the form of intense heat sensation and pain. Far from being a setback, these symptoms warn the device user to move the handpiece to another part of the treatment area (5).

Treatment was carried out on all areas with the same power density of 27 joules/cm<sup>2</sup> for 15 minutes, so that the temperature of the skin detected externally reached between 40 and 42°C.

For treatment, the face was first washed with a mild gel (*Tt gel limpiador suave*, Laboratorio Profarplan, Barcelona, Spain). The patient adopted the lateral supine position. The transparent gel was applied to the skin (*Transonic gel*, Lab. Telic Barcelona, Spain). Then, the handpiece was applied over the selected area. During treatment, the handpiece was firmly held against the skin to ensure good contact of the electrodes. The handpiece was moved by sliding up and down following the Langerhans lines, applying pressure with the upwards displacements. A minimum of 12 passes were performed with the handpiece on each of the lines of treatment. The patient was asked to advise as to experiencing excessive heat, pain and/or intense heat sensation so that the handpiece could be moved to another line of treatment. Also, if the temperature increased to above 41°C, or the skin became excessively reddish, the handpiece was

moved to the continuous line of treatment. The temperature of the skin's surface was monitored with an infrared thermometer (IR Surface Thermometer A 28886 Zenit Measuring/Testing Instruments™, USA). If increased temperature was reached in the new line treated, treatment returned to the previous line until the twelve treatment passes had been performed.

Upon finishing treatment, the skin was gently cleaned with dry gauze and a mild Prednicarbonate ointment was massaged into the skin (Lab. Telic Barcelona, Spain).

## Evaluation

Treatment results were assessed both subjectively and objectively. For the subjective evaluations, it was explained to each patient that prior to commencing the series of treatments, skin condition had a Baseline Score of 0, and that they were to award a score on an analogical scale one month after the last session, reflecting their appreciation of the results of the treatment. They were asked to award between 1 and 25 for Minimal improvement; Fair improvement between 26 and 50; Good from 51 to 75, and Very Good from 76 to 100. It was also explained to them that worsening of the condition of the treated area should be scored below the Baseline Score, 0. When awarding scores, patients were to take into account the texture, wrinkle appearance and any change to the skin in comparison with the start of the treatment series.

For objective assessment, an expert medical doctor, unfamiliar with the study protocol and details of the treatment, assessed the results using the same means of scoring as used by the patients. To this end, the medic examined the photographs of before, and one month after the last session.

Objective assessment of the changes in skin texture was also carried out by means of comparing photographs of the skin surface obtained by direct contact, by placing the high definition digital camera lens on the skin. (CLINIPRO, Diagnosis System,

Barcelona, Spain). This system of contact digital macrophotography can be used for comparative and statistical analysis of the 3D characteristics of the relief of the skin surface in order, based on the results, to deduce its texture.

The photography carried out using this surface optical camera enables examining the anisotropy of the skin's external micro-relief. Measurement analyses the skin's general physical properties, which are determined according to the variation it displays in the light propagation phenomena and which translate into micras surface depth and roughness.

In preparing for photography, the area for examination was marked out taking anatomical reference points and using transparent paper placed over the surface of the face so as to be able to perform precise, comparative control of the photographs taken prior to the series of treatments, with those taken one month after the last treatment.

Measurements were taken using a programme especially designed for the system of analysis. The images were taken with the patient standing. The camera optic was positioned vertically on the cutaneous surface of the corresponding area harnessing a three dimensional micro-topographic image which was recorded by optical triangulation scanner, with a video light projection technique and digital image processing.

Once the image was digitalised, it was transferred to the computer for evaluation. The computer programme took quantitative measurements obtaining a calculation of algorithms for the translation of the photographed data (6).

## **Results**

During treatment, patients experienced heat sensation and some pain, but none abandoned treatment. After the session, the skin appeared plumper displaying slight congestion and erythema. The skin appeared shiny and its aspect visibly improved.

One month after the last treatment, patients qualified the results of the sessions as: 6, Very Good; 12, Good and 2, Fair. No Bad results were observed (Table 2). The medical doctor who examined the photographs evaluated the results as: 7, Very Good; 12, Good and 1, Fair. (Figs. 1 to 3). The results of the analysis of the image of the cutaneous surface were: 10, Very Good and 10, Good (Fig.4).

## **Discussion**

In all treatment of cutaneous aging, the rapid recovery of the characteristics of young skin are sought, ideally with no side effects (7,8). Several types of treatment have been proposed, including cosmetic and technical products that contribute advantages and improve results (9-12). With RF treatment, the discomfort and erythema experienced by patients is mild. Treatment with RF AMFLI *Thermalipo<sup>TM</sup>II* technology is well accepted by patients who experienced heat sensation which increased as the treatment session progressed, but none ceased treatment. Heating to between 41 and 42°C generally corresponded with the appearance of pain. It is precisely at this moment that the patient undergoes intense heat sensation whereby the handpiece transmitting the RF must be moved to another line of treatment in order to avoid potentially burning the skin. The handpiece must return to the previous area, repeating this manoeuvre until a minimum of 12 passes have been performed in order for the heat accumulated inside the skin to have the effect of causing irritation in the dermis and thus bring about mechanisms to repair the thermal micro-aggression which leads to the formation of new collagen. The development of new fibres and the increased vascularisation as a result of the hyperthermia produced by the RF, despite being a reaction to a non-specific irritation of the tissue, is effective since it causes the skin to tense, improves wrinkle aspect and cutaneous texture. It is advisable to perform several passes to maintain a high

thermal gradient in dermis in order to obtain efficient results. This has been observed in previous studies carried out on the face and other parts of the body using RF (13).

Also important is the direction in which the handpiece is moved during treatment. According to our observations, movements in an ascending direction, following the anatomical lines of tension, achieve better results than if treatment is done irregularly, with random movements of the handpiece. Displacement of the handpiece in an upward direction, should produce a better outcome on the skin tension and in redirecting collagen fibres. These affects would be a consequence of the heating of tissue produced by the RF and the pressure exerted by the handpiece during treatment (14). Fibres, typically displayed randomly and separated in aged and elastotic skins would undergo changes in their disorganised arrangement. Change will take place in fibre architecture as a result of the heating occurring within the dermis. When displacing the handpiece with ascending pressure, collagen fibres will realign resulting in improved tension and skin aspect (15).

Heat propagation to the skin, resulting from the relatively prolonged treatment session, dissipates in all directions. The consequences of this thermal increase are beneficial to the cell metabolism and lymphatic drainage in the treated area. Likewise, heat diffusion, also towards the epidermis, is a useful warning sign, since when the patient notices it, she advises the user in time to avoid potential burning. The pain, which traduces temperature increase, means that treatment must be carried out continuously moving the handpiece.

In the series of patients we present, no complications were observed. No burning occurred, and neither were there any cases of prolonged residual erythema or changes in skin pigmentation. Nevertheless, we have observed that when the handpiece is moved over bony prominences, the patient expresses discomfort and often pain. This would be

due to the proximity of the osseous prominences and occurs particularly at the level of the edges of the lower jaw.

The rhythm of sessions would also have a positive impact on the results. Treatment sessions carried out every two weeks manage to maintain the increased tissue stimulation produced by the thermal effect of the electrical energy absorbed in dermis. The various treatment sessions, which last a minimum of 15 minutes, achieve measurable results as of the fourth or fifth session. Subjectively, patients inform of improved cutaneous texture and an anti-flaccidity effect.

Upon terminating RF AMFLI treatment of the face, it is advisable to use sun block since exposure to UV rays increases the metalloproteinase which degrade the collagen fibres, countering the effects sought by the RF to stimulate collagen (16). Likewise, the use of dermo-cosmetic creams is indicated to maintain improvements achieved between RF sessions. Immediately after the end of each treatment, the application of aloe vera gel on the treated area alleviates any residual symptoms such as heat sensation in the skin.

Objectively, analysis of the photography of the epidermis skin surface, which clearly showed an improvement in condition, is indicative of the beneficial, complication-free action of RF AMFLI.

## **Conclusions**

The sessions carried out every 2 weeks to combat the signs of cutaneous aging, totalling 6 treatments with RF AMFLI, are beneficial from the point of view of practicality. Treatment is simple and complication-free. However, the indication as to the continuous movement of the handpiece must be heeded, pressing firmly on the treated area and

maintaining thermal increase for a minimum period of fifteen minutes. For the areas treated on the face, neck and periocular region, both the subjective and the objective assessments demonstrated the efficacy of the treatment.

## **Acknowledgements**

The authors hereby declare that they have no financial or any other interest in the companies and/or equipment mentioned in this study.

The conclusions of this study are recorded in the academic activities of the Antoni de Gimbernat Foundation, 2008-2009.

## Figure Legends

### Figure 1

Patient 45 years of age, phototype III, degree II wrinkles, presenting clear signs of aged skin (A). (B), 1 month after 6 treatment sessions have been carried out. Note the improvement achieved in the tone of the cutaneous tissue and in the external aspect of the skin.

### Figure 2

Patient 56 years of age, phototype IV-V, degree III wrinkles. (A), clear signs of cutaneous aging with periocular flaccidity and wrinkles. (B), aspect 1 month after the last treatment session. Clear improvement in the aspect of the skin and wrinkles.

### Figure 3

Patient 40 years of age, phototype II, degree II wrinkles. (A), prior to treatment, observe fine skin with periocular wrinkling and evident crow's feet. (B), results 1 month after 6 treatment sessions using *Thermalipo*<sup>TM</sup>. Clear improvement of the skin and wrinkles.

### Figure 4

Graphic representation of the 3D images taken using a high definition optic, once processed by computer. The figures are placed side by side for comparison. The two analyses correspond exactly to the same periocular region.

Images A, A<sub>1</sub> and A<sub>2</sub> correspond to the baseline for assessment prior to commencing treatment sessions.

A, is the image of the right lateral periocular skin surface (crow's feet). Observe the representative image of a wrinkle.

A<sub>1</sub>, is the image of A presented in 3D for more precise analysis. The signs of aging are characteristic.

$A_2$ , this graph is the mathematical product of the irregularities of the skin's surface obtained after analysis of roughness, using logarithmic tables and computer calculations.

B,  $B_1$  and  $B_2$  are the images of one month after the 6<sup>th</sup> treatment session. Note the flattening of the surface of the skin which, in  $B_1$ , is a more homogenous wrinkle, translating improvement and flattening of the cutaneous surface. In graphic  $B_2$ , the flattening of the lines indicates an improvement in roughness and, consequently, a better texture.

## References

1. Sadick NS. The radiofrequency frontier: A review of radiofrequency and combined radiofrequency pulsed-light technology in aesthetic medicine. *Facial Plast Surg*. 2005; 21:1188-98.
2. Alster TS, Tanzi E. Improvement of neck and cheek laxity with a non-ablative radiofrequency device: a lifting experience. *Dermatol Surg* 2004; 30: 503-7.
3. Sadick N.S., Trelles M.A. (2005) Nonablative Wrinkle Treatment of the Face and Neck Using a Combined Diode Laser and Radiofrequency Technology. *American Society for Dermatologic Surgery, Inc.* 2005;.31: 1695-1699.
4. Zelickson BBD, Kist D, Bernstein E, Brown DB, Ksenzenko S, Burns J, Kilmer S, Mehregan D, Pope K. Histological and ultrastructural evaluation of the effects of a radiofrequency-based nonablative dermal remodelling device: A pilot study. *Arch Dermatol* 2004; 140:204-209.
5. Romero C, Caballero N, Herrero M, Ruíz R, Sadick N.S, Trelles M.A. Effects Of cellulite treatment with RF, IR Light, mechanical massage and suction treating one buttock with the contralateral as a control. *Journal of Cosmetic and Laser Therapy*. 2008; 10:193-201.
6. Caballero N, Herrero M, Ruíz R, Romero C, Trelles M.A. Mejoría de la condición estética de la piel con tratamientos combinados de luz LED y Ácido Hialurónico. *Medicina estética*. 2007; 13:36-45.
7. Del Río R., Cisneros J.L, Castells A. Nuevas fuentes de energía en Dermatología. *Láser en Dermatología y Dermocosmética*. 2008; 14:521-524.
8. de Felipe I, Del Cueto SR, Perez E, Redondo P. Adverse reactions alter nonablative radiofrecuencia: Follow-up of 290 patients. *J Cosmet Dermatol* 2007; 6:163-166.

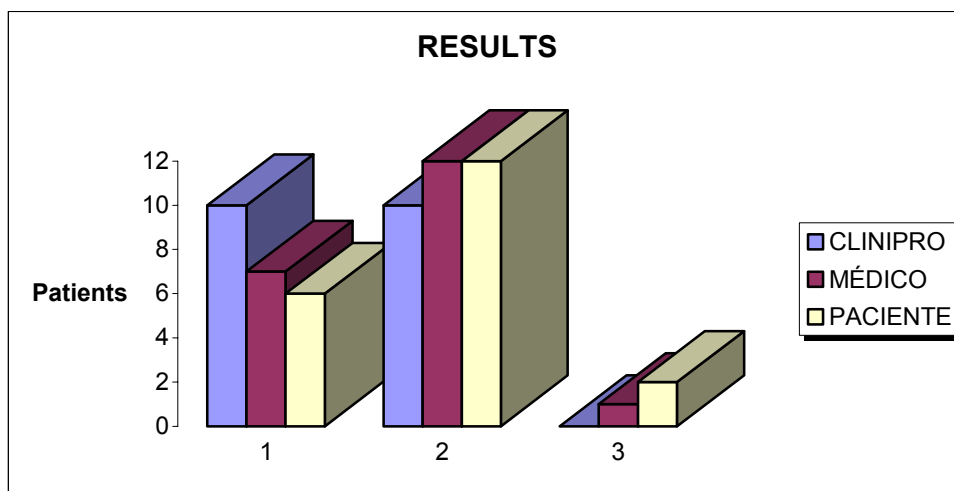
9. Trelles M.A., Velez M, Garcia-Solana M.L., Allones I. Ensayo Clínico y de Laboratorio de una Crema de Caléndula en el Post Resurfacing Láser. *Cirugía Plástica Ibero-latinoamericana* Enero-Febrero-Marzo 2003; 29-1: 11-24.
10. Singh M, Griffiths CE. The use of retinoids in the treatment of photoaging. *Dermatol Ther* 2006; 19:297-305.
11. Coimbra M, Rohrich RJ, Chao J, Brown SA. A prospective controlled assessment of microdermabrasion for damage skin and fine rhytides. *Plast Reconstr Surg* 2004; 113:1438-1443.
12. Karimipour DJ, Kang S, Johnson TM, Orringer JS, Hamilton T, Hammerberg C, Voorhees JJ, Fisher G. Microdermabrasion: A molecular analysis following a single treatment. *J Am Acad Dermatol* 2005; 52:215-223.
13. Trelles M.A., Mordon S. Cutaneous effects compared between higher fluence with fewer treatments and lower fluence with more treatments in a combined IR laser/radio frequency system. *Journal of Cosmetic and Laser Therapy*. 2006; 8: 177-183.
14. Van Der Lugt C, Romero C, Ancona D, Al-Zarounis M, Perera J, Trelles M.A. A multicenter study of cellulite treatment with a variable emission radio frequency system. *Dermatologic Therapy* 2009; 22: 74-84.
15. Hoffman AH, O'Connor JP, Grigg P. Realignment of Collagen Fibers in Mouse Skin. *Proceedings Book, FASCIA Research Congress Oct.2007*.
16. Cisneros J.L., Del Río R., Querol I., Martí M., Brichs A., Trelles M.A., Vélez M. Radiofrecuencia volumétrica en la flacidez cutánea. *Láser en Dermatología y Dermocosmética*. 2008; 14.2:535-540.

**TABLE 1**

Patient characteristics

<b>Patients</b>	<b>Age</b>	<b>Phototype</b>	<b>Patients</b>	<b>Age</b>	<b>Phototype</b>
1	45	IV	11	52	IV
2	52	III	12	60	II
3	42	II	13	43	III
4	48	IV	14	47	II
5	46	III	15	51	IV
6	50	III	16	59	IV
7	58	II	17	48	III
8	49	III	18	41	III
9	45	IV	19	50	II
10	47	II	20	40	IV

**TABLE 2**



<b>1 Very Good</b>
2 Good
<b>3 Regular</b>